Basaloid Squamous Cell Carcinoma of the Sinonasal Tract

Jacqueline A. Wieneke, M.D.
Lester D. R. Thompson, M.D.
Bruce M. Wenig, M.D.

Department of Endocrine and Otorhinolaryngic-Head and Neck Pathology, Armed Forces Institute of Pathology, Washington, DC.

Presented at the 85th Annual Meeting of the United States and Canadian Academy of Pathology, Orlando, Florida, March 23–29, 1996.

Address for reprints: Bruce M. Wenig, M.D., Dept of Pathology, Montefiore Medical Center, 111 East 210th Street, Bronx, NY 10467, Washington, DC 20306-6000.

The opinions or assertions contained herein are the private views of the authors and are not to be construed as official or as reflecting the views of the Department of the Army, the Department of Defense, or the Department of the Navy.

Received April 28, 1998; revisions received July 30, 1998, and August 25, 1998; accepted August 25, 1998.

BACKGROUND. Basaloid squamous cell carcinoma (BSCC) is a high grade, aggressive variant of squamous cell carcinoma with a predilection for the larynx, hypopharynx, tonsils, and base of the tongue. To the authors' knowledge, BSCC originating in the nasal cavity and paranasal sinuses rarely has been reported.

METHODS. Fourteen cases of BSCC involving the nasal cavity and paranasal sinuses were identified in the files of the Otolaryngic-Head and Neck Pathology Tumor Registry of the Armed Forces Institute of Pathology from 1975–1997. Clinical records and follow-up were available in all cases. Paraffin blocks were available for histochemical and immunohistochemical studies in all cases.

RESULTS. There were 7 females and 7 males, ages 32–86 years (median, 66.5 years; mean, 62 years). The patients presented primarily with a mass lesion and unilateral nasal obstruction. In nine patients the tumor was confined to the nasal cavity. In three patients the tumor involved the sinuses alone and in two patients the tumor involved the nasal cavity and paranasal sinuses. Histologically, the tumors were widely invasive with a variety of growth patterns, including lobular, solid, trabecular, cribriform, and fascicular. The neoplastic infiltrate included predominantly pleomorphic, basaloid-appearing cells with hyperchromatic nuclei, inconspicuous to prominent nucleoli, and a variable amount of eosinophilic to clear-appearing cytoplasm. Mitotic figures, including atypical forms, were readily apparent as was necrosis (individual cell and comedo-type). Foci of squamous differentiation were limited in extent but were found in all cases and included squamous whorls, individual cell keratinization, and intercellular bridges. Intraepithelial dysplasia, carcinoma in situ, or invasive squamous carcinoma was present in all cases. Other histologic features included intercellular stromal hyalinization and peripheral nuclear palisading. In two cases, neural-type rosettes were found. Immunoreactivity for a variety of epithelial markers including cytokeratin (AE1/AE3/LP34), CAM 5.2, 34βE12, CK7, and epithelial membrane antigen was present in all cases. Variable reactivity was present with vimentin, actins (smooth muscle and muscle specific), neuron specific enolase, S-100 protein, glial fibrillary acidic protein, CK20, carcinoembryonic antigen, Leu7, and Ewing's marker. Chromogranin, synaptophysin, neurofibrillary protein, leukocyte common antigen, HMB-45, desmin, and Epstein–Barr virus latent membrane protein were absent. Surgical resection was the treatment of choice. Eight patients had recurrent or persistent tumor and metastatic disease occurred in five patients. At last follow-up, 7 patients (50%) had died of disease with a median survival of 12 months from the time of diagnosis and 3 patients were alive with disease over periods ranging from 8 months-5 years. Of the 4 remaining patients, 2 were alive without disease at 1 month and 5 years, respectively, 1 patient was lost to follow-up with no evidence of tumor at 3 years, and 1 patient had died of unrelated causes with no evidence of disease.

CONCLUSIONS. Sinonasal BSCC is a histologically distinct variant of squamous cell

© 1999 American Cancer Society

carcinoma with pathologic features and aggressive biologic behavior similar to BSCC localized to more common mucosal sites of the upper aerodigestive tract.
***Cancer* 1999;85:841–54.** © *1999 American Cancer Society.*

KEYWORDS: sinonasal tract, basaloid squamous cell carcinoma, treatment, prognosis, differential diagnosis, immunohistochemistry.

Basaloid squamous cell carcinoma (BSCC) was first reported by Wain et al.[1] and subsequently has been confirmed to be a high grade variant of squamous cell carcinoma with a predilection for the supraglottic larynx, hypopharynx (pyriform sinus), tonsil, and the base of tongue.[2–10] BSCC is not limited to these head and neck sites and occurs in a variety of other upper aerodigestive tract areas, including the oral cavity, nasopharynx, and trachea.[11–17] To the best of our knowledge, only three cases of BSCC of the sinonasal tract have been reported in the literature.[5,18,19] It is due to the limited number of cases reported in the sinonasal tract that we undertook this study. We report the clinicopathologic features of 14 cases of sinonasal BSCC and contrast these features with those of BSCC involving more usual upper aerodigestive tract sites. We also discuss the differential diagnosis of these tumors in general and to sinonasal tumors specifically.

MATERIALS AND METHODS

Fourteen cases of BSCC originating in the nasal cavity and paranasal sinuses were identified in the files of the Otolaryngic-Head and Neck Pathology Tumor Registry at the Armed Forces Institute of Pathology between 1975–1996. Clinical records were available in all cases and follow-up data were available in all cases. The light microscopic features were evaluated. Histochemical staining included periodic acid–Schiff (PAS) with and without diastase digestion and Mayer's mucicarmine.

Paraffin blocks were available for immunohistochemistry in all cases. Five-micron sections from paraffin embedded tissue blocks were prepared for immunohistochemical analysis according to the standardized avidin-biotin complex method of Hsu et al.[20] The basic commercially prepared antibody panel for each case included a cytokeratin cocktail (AE1/AE3/LP34) (mouse monoclonal, 1:200 AE1/AE3 from Dako Co., Carpinteria, CA; and 1:40 CK1 from Boehringer–Mannheim, Indianapolis, IN), CAM 5.2 (mouse monoclonal; 1:50; Becton Dickinson, San Jose, CA), cytokeratin 7 (CK7) (mouse monoclonal, 1:200; Dako Co.), cytokeratin 20 (CK20) (mouse monoclonal, 1:50; Dako Co.), 34βE12 (K903) (mouse monoclonal, 1:40; Enzo Diagnostics, Farmingdale, NY), chromogranin (mouse monoclonal, 1:3200; Boehringer–Mannheim), synaptophysin (rabbit polyclonal; 1:400; Dako Co.), neuron specific enolase (NSE) (mouse monoclonal; 1:200; Dako Co.), Leu7 (mouse monoclonal; 1:20; Becton Dickinson), neurofilament protein (NFP) (mouse monoclonal; 1:200; Dako Co.), glial fibrillary acid protein (GFAP) (rabbit polyclonal; 1:2000; Dako Co.), leucocyte common antigen (LCA) (mouse monoclonal; 1:100; Dako Co.), S-100 protein (rabbit polyclonal, 1:800, Dako Co.), HMB-45 (mouse monoclonal; 1:100; Dako Co.), CD99 (Ewing's marker) (mouse monoclonal; 1:20; Dako Co.), vimentin (mouse monoclonal, 1:800; Biogenex Laboratories, San Ramon, CA), muscle specific actin (HHF35) (mouse monoclonal; 1:80; Enzo), smooth muscle actin (mouse monoclonal; 1:8000; Sigma, St. Louis, MO), desmin (mouse monoclonal; 1:100; Dako Co.), carcinoembryonic antigen (CEA) (rabbit polyclonal, 1:800; Dako Co.), epithelial membrane antigen (EMA) (mouse monoclonal, 1:800, Dako Co.), Epstein–Barr virus latent membrane protein (EBV-LMP) (mouse monoclonal, 1:40; Dako Co.). Of the antibodies, cytokeratin cocktail, CK7, CK20, Cam 5.2, CEA, EMA, Ewing's marker, GFAP, NFP, and EBV-LMP required protease predigestion. Positive and negative controls were used.

RESULTS

The clinicopathologic features are presented in detail in Table 1. There were 7 females and 7 males, ranging in age from 32–86 years (median, 66.5 years; mean, 62 years). The most common clinical reported symptom was that of a mass lesion and unilateral nasal obstruction. Additional signs and symptoms included epistaxis, visual disturbances, sinusitis, and headache. In nine patients (Cases 1–3, 7, 9, and 11–14), the tumor was confined to the nasal cavity. Two patients (Cases 4 and 5) had tumor involving the nasal cavity with extension into the paranasal sinuses. Three patients (Cases 6, 8, and 10) had tumor involving the paranasal sinuses only. Eight of the tumors were on the left side, five were on the right side, and one was bilateral. Radiologic findings were available in five patients (Cases 3, 6, 7, 10, and 12). Computed tomography scan and magnetic resonance imaging varied from a nasal cavity mass without bone or soft tissue destruction (Cases 7 and 12) to extensive invasive growth includ-

TABLE 1
Basaloid Squamous Cell Carcinoma—Clinical Results

Case no.	Age (yrs)	Gender	Symptoms	Location	Tobacco/ alcohol/ other	Therapy	Recurrence	Metastases/local Invasion	Clinical outcome
1	53	F	Epistaxis	Nasal septum, L	No/no/no	S, R, C	2 at 2 and 8 yrs	None	Dead, DD, 8 yrs
2	81	F	Obstruction	Nasal cavity, R	Unk	S	None	None	Alive, LTF, 3 yrs
3	69	M	Blurred vision	Nasal cavity, L	No/no/no	S	1 within 1 yr	None	Dead, DD, 1 yr
4	32	M	Obstruction	Nasal cavity & sinus, R	Yes/yes/no	S	Many, local, within 1 yr	Brain	Dead, DD, 7 yrs
5	72	M	Obstruction	Nasal cavity & sinus, L	Yes/unk/yes[1]	S	1 within 6 mos	Brain (ext)	Dead, DD, 1 yr
6	33	F	Obstruction and diplopia	Sinuses, bilateral	Unk	S, R, C	None	Bone & lung	Dead, DD, 1 yr
7	41	F	Obstruction	Nasal cavity, L	No/no/no	S, R for RD	Multiple at 2, 3, 4, 5 yr	Lung	Alive, RD, 2, 3, 4, and 5 yrs
8	75	F	Obstruction	Sinus, L	Unk/unk/yes[2]	S, R	1 at 2 yrs	None (ext to dura)	Alive, RD, 2 yrs
9	64	M	Nasal mass	Nasal cavity, L	No/yes/no	S	None	None	Dead, NED, 4 yrs
10	79	F	Sinusitis and headache	Sinuses, L	Yes/no/no	S	1 within 1 yr	Bone & lung	Dead, DD, 1 yr
11	56	M	Nasal mass	Nasal septum, R	Yes/no/yes[3]	S, R	None	Cervical lymph nodes	Alive, NED, 2 yrs
12	46	M	Obstruction and epistaxis	Nasal septum/cavity, R	No/no/no	S, R for RD	1 within 8 mos	None	Alive, RD, 8 mos
13	86	F	Bulky nasal mass	Nasal septum/turbinate, L	Yes/no/no	Biopsy only	None	None	Dead, DD, 6 mos
14	79	M	Intranasal mass	Nasal cavity, R	No/no/yes[4]	S, R	None	None	Alive, NED, 1 mo

F: female; M: male; L: left; R: right; Unk: unknown; S: surgery; R: radiation therapy; C: chemotherapy; yr: year(s); DD: dead of disease; LTF: lost to follow-up; RD: recurrent disease; ext: extension; NED: no evidence of disease.

[1] Paint solvent exposure.

[2] Radiation for olfactory neuroblastoma.

[3] Chromate exposure.

[4] Radiation for childhood acne.

ing destruction of the clivus, posterior clinoid processes, and pituitary fossa (Case 3), invasion of the skull base, clivus, pituitary fossa, and bilateral cavernous sinuses (Case 6), and invasion of the posterior orbit with destruction of the floor of the anterior cranial fossa (Case 10).

Six of the patients reported tobacco and/or alcohol use; five patients denied tobacco or alcohol use. In three patients, the use of tobacco and/or alcohol was not known. Two patients (Cases 8 and 14) had a prior history of radiation exposure, one for the treatment of a purported olfactory neuroblastoma 6 years prior to the development of sinonasal BSCC (Case 8) and one for the treatment of childhood acne decades prior to the development of sinonasal BSCC (Case 14). Two patients had chemical exposure, including paint solvents (Case 5) and chromate (Case 11). Other than the patient with a previous diagnosis of olfactory neuroblastoma, none of the patients had a prior, concurrent, or subsequent malignant tumor of the upper aerodigestive tract or of any other site.

Surgery was the treatment of choice in 13 patients with adjuvant radiation therapy in 5 patients and chemotherapy in 2 patients. One patient (Case 13) underwent biopsy only and refused any additional therapy. Eight patients had locally recurrent tumor or persistent disease. Of these eight patients, four had recurrence of their tumors within the first year after the diagnosis. The recurrences in the other 3 patients occurred within 2 years of the diagnosis. Metastatic disease occurred in five patients, two involving the bone and lung (Cases 6 and 10), one to the lung only (Case 7), one to the brain (Case 4), and one to regional lymph nodes (Case 11). In two other patients (Cases 5 and 8) the tumor invaded directly to the brain and dura, respectively. Of the 14 patients, 10 (71%) either died of disease (n = 7) or were alive with disease (n = 3) at last follow-up. The average and median time to death from the time of diagnosis was 33.4 months and 12 months, respectively. One patient died of unrelated causes 4 years after the diagnosis with no evidence of disease. At last follow-up 2 patients were alive without disease at 1 month and 5 years after the diagnosis. One patient was lost to follow-up 3 years after the diagnosis. At her last follow-up there was no evidence of disease.

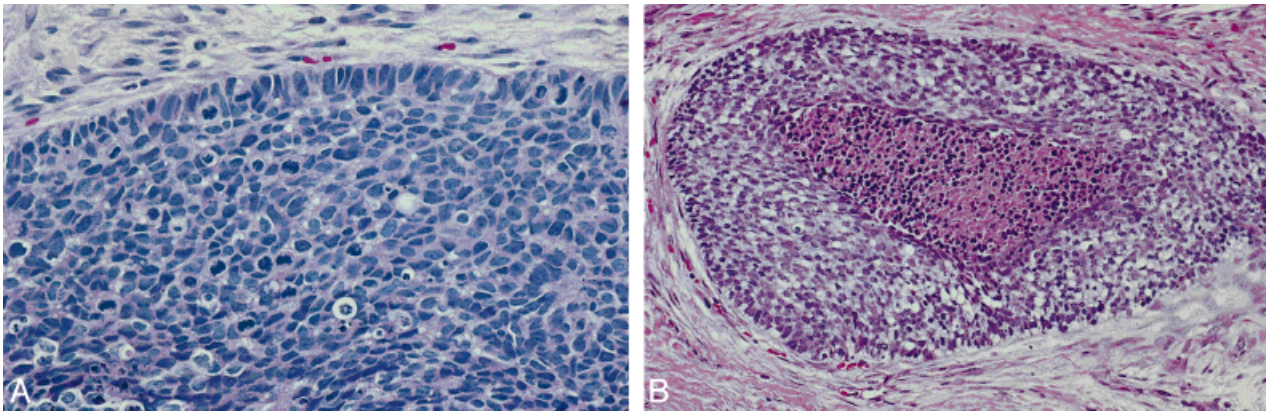

FIGURE 1. (A) The neoplastic infiltrate of sinonasal basaloid squamous cell carcinoma (BSCC) is dominated by basaloid cells comprised of pleomorphic and hyperchromatic nuclei with increased nuclear-to-cytoplasmic ratio, and increased mitotic activity, including atypical mitoses and nuclear palisading at the periphery of the neoplastic lobule without associated stromal retraction (Case 5). (B) A characteristic feature of BSCC is the presence of comedonecrosis in the center of the neoplastic lobules. In addition, this focus shows clear cytoplasmic changes (Case 3).

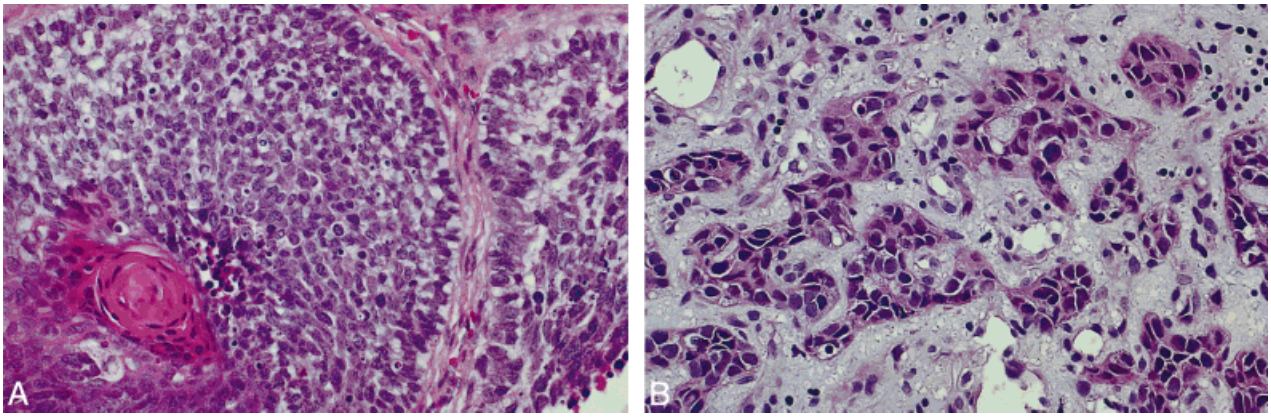

FIGURE 2. Squamous differentiation represents the minor component in basaloid squamous cell carcinoma. (A) Abrupt keratinization is observed in the center of an invasive lobule that is comprised predominantly of pleomorphic basaloid cells (Case 3). (B) Less often, foci of invasive squamous cell carcinoma were observed (Case 4).

Pathology

The lesions ranged in size from 1.5 cm to 4 cm in greatest dimension. The lesions variably were described by endoscopic examination as polypoid, papillary, and exophytic.

Microscopically, the tumors were comprised of a cellular infiltrate that consisted predominantly of basaloid-appearing cells characterized by hyperchromatic nuclei with marked nuclear pleomorphism, an increased nuclear-to-cytoplasmic ratio, eosinophilic to amphophilic to clear cytoplasm, and indistinct to prominent eosinophilic nucleoli (Fig. 1). There was marked increase in mitotic activity and atypical mitoses were readily evident. A characteristic feature was the presence of confluent foci of necrosis in the central areas of the neoplastic lobules (comedo-type necrosis), as well as individual cell necrosis (Fig. 1). Nuclear palisading with alignment of the nuclei in a perpendicular arrangement could be observed at the periphery of the neoplastic lobules but associated stromal retraction was not present (Fig. 1).

In addition to the dominant basaloid cell population, an associated squamous cell component was present (Fig. 2). The foci of squamous cell differentiation were present in all cases but varied from readily apparent to limited, scattered foci. These areas of squamous differentiation included abrupt keratinization in the form of squamous pearls, individual cell keratinization, or invasive keratinizing squamous cell carcinoma. The squamous cell foci could be observed intimately admixed with the basaloid cell infiltrate or were observed adjacent to these areas. Surface epithelial alterations were present in all the cases and included a variable degree of epithelial dysplasia to car-

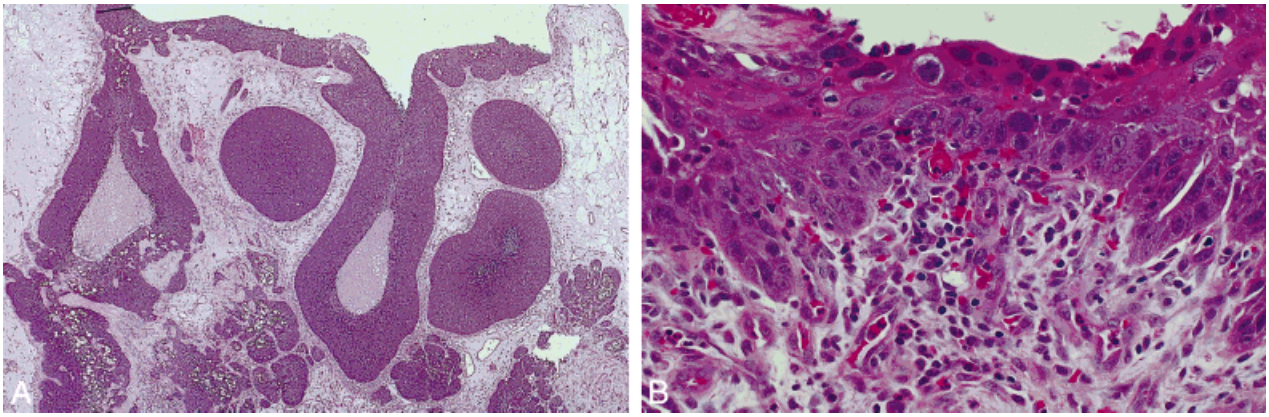

FIGURE 3. Surface epithelial alterations were present in all the cases. (A) Carcinoma in situ giving rise to invasive carcinoma (Case 9). (B) Epithelial dysplasia in sinonasal epithelium that has undergone squamous metaplasia (Case 3).

cinoma in situ giving rise to invasive carcinoma (Fig. 3). The intact, uninvolved surface epithelium was a ciliated respiratory type and foci of squamous metaplasia were variably present. In addition, surface epithelial ulceration with associated necrosis could be observed.

The neoplasms were infiltrative and showed a variety of growth patterns. The most common infiltrative patterns were lobular or solid, which were observed in all 14 cases. Less common patterns included cribriform, tubular, trabecular, or fascicular (Fig. 4). The two cases with a fascicular growth (Cases 3 and 7) were comprised of spindle-shaped pleomorphic cells with elongated to ovoid nuclei (Fig. 5). These areas were limited in extent and were observed in a tumor that otherwise had typical features of BSCC. In two cases (Cases 7 and 10) there were true neural-type rosette formation (Fig. 5), and in one case (Case 9) microcalcifications were present. Intercellular stromal hyalinization and mucohyaline deposition were present (Fig. 6). The tumors were extensively invasive with neurotropism, lymph-vascular space invasion, and osseous and soft tissue invasion. In Case 12, metastatic carcinoma was present in cervical lymph node metastasis which was similar in appearance histologically to the primary intranasal tumor. The lymph node metastasis effaced the lymph node architecture with nearly complete replacement of the lymph node and extranodal extension was present.

Histochemical evaluation showed the presence of intracytoplasmic and intraluminal diastase sensitive, PAS positive material in 4 of 14 cases (Cases 3, 4, 7, and 10). The intercellular stromal hyalinized material was PAS positive. Mucicarmine staining was not present.

Immunohistochemistry

Results of immunohistochemistry are shown in Table 2. The low and high molecular weight keratin cocktail was reactive in all 14 cases in both the basaloid and squamous cell components (Fig. 7). EMA staining was present in all 14 cases but varied from diffuse to focal to rare in both the basaloid and squamous components. CAM 5.2 was positive in 12 of 14 cases with variable intensity and variable distribution. CEA was present in 4 of 14 cases and when reactive tended to predilect to the squamous foci. CK7 was positive in 10 of 14 cases also with variable intensity and variable distribution. CK20 was focally present in only 1 case (1 of 14). 34βE12 reactivity was present in 12 of 14 cases with variable intensity and variable distribution but tended to be more intensely reactive in the basaloid cells (Fig. 7).

In addition to the epithelial markers, variable reactivity was observed with S-100 protein (6 of 14 cases), NSE (10 of 14 cases), GFAP (2 of 14 cases), and vimentin (8 of 14 cases) (Fig. 7). Vimentin staining was observed diffusely within the cytoplasm; in two cases, perinuclear punctate reactivity was observed. Seven of 14 cases showed reactivity with muscle specific actin whereas 6 of 14 cases were positive for smooth muscle actin (Fig. 7). Focal reactivity was present in one case with Leu7 but no reactivity was observed in any of the cases with the chromogranin and synaptophysin. Similarly, no immunoreactivity was present with NFP, LCA, HMB-45, and desmin. Ewing's marker (CD99) showed focal positivity in seven of the cases (Fig. 7).

DISCUSSION

BSCC is a histologically distinct variant of squamous cell carcinoma. The head and neck region appears to represent the most frequent area of occurrence of

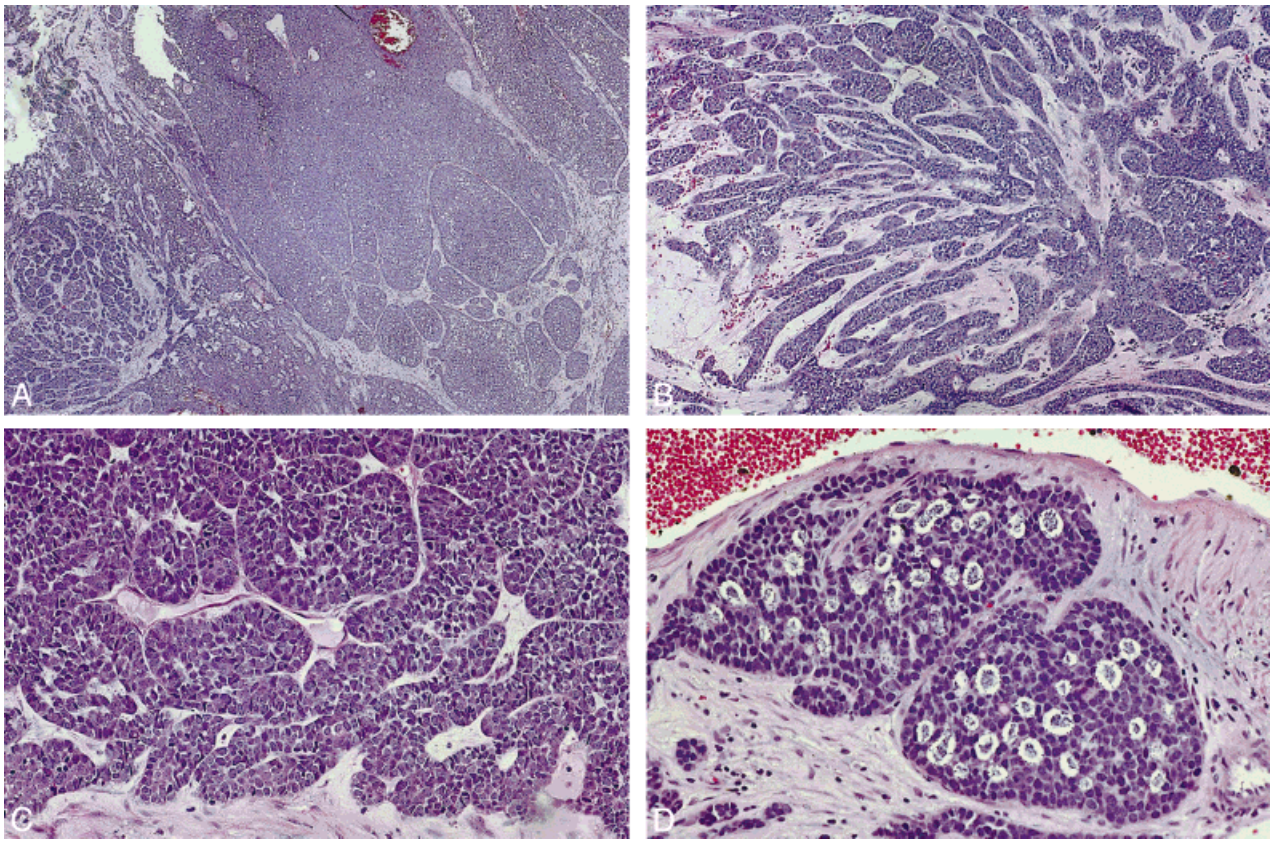

FIGURE 4. Sinonasal basaloid squamous cell carcinoma shows a variety of growth patterns, including: (A) solid (Case 6), (B) trabecular (Case 5), (C) lobular (Case 4), and (D) cribriform (Case 12).

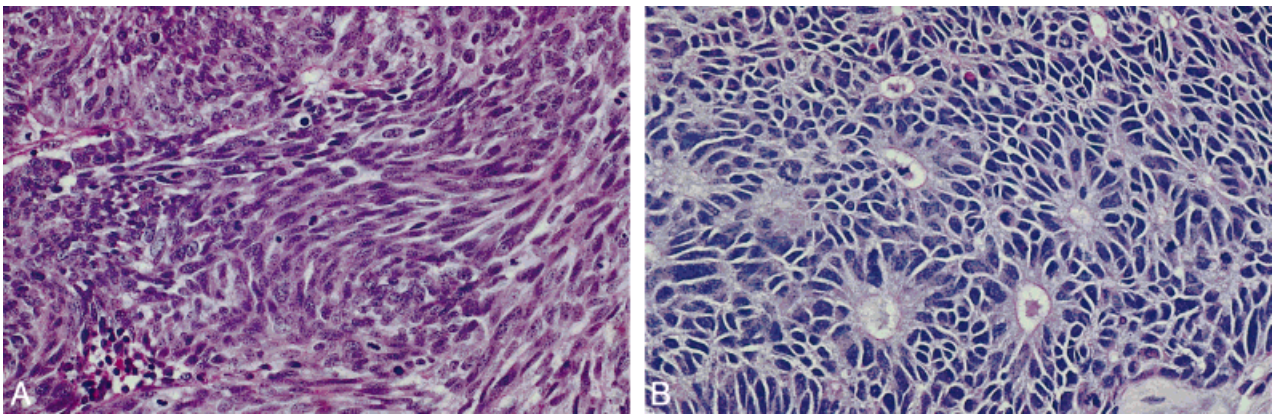

FIGURE 5. Unusual features observed in sinonasal basaloid squamous cell carcinoma include: (A) fascicular growth comprised of spindle-shaped cells (Case 3) and (B) true neural-type rosettes (Case 10).

BSCC with a predilection for the supraglottic larynx, hypopharynx, tonsil, and base of tongue.[1–10] However, BSCC is found in other mucosal sites of the upper aerodigestive tract,[11–19] as well as nonhead and neck sites, including the esophagus,[21–23] lung and bronchus,[24–26] thymus,[27] anus,[28] and uterine cervix.[29,30] Upper aerodigestive tract BSCC affects men more than women and typically occurs in older individuals. BSCC of upper aerodigestive tract sites is an aggressive, high grade tumor with an increased tendency to be deeply invasive, multifocal, and metastatic even at the initial presentation.[1] Shallow biopsies may belie the depth and extent of invasion and may not be representative of the lesion, leading to erroneous staging. Multifocal

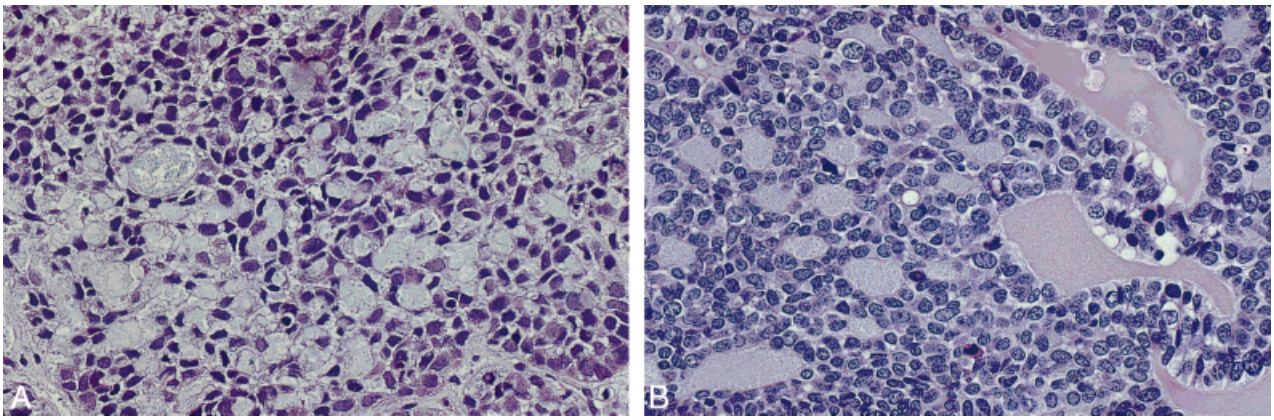

FIGURE 6. (A) Intercellular stromal hyalinization (Case 12) and (B) mucohyaline deposition (Case 9). These features along with the varied growth patterns, may simulate the appearance of a salivary gland neoplasm.

TABLE 2
Basaloid Squamous Cell Carcinoma: Immunohistochemical Results

Immunohistochemical marker	Total no. positive
Keratin (AE1/AE3 + LP3)	14/14
Epithelial membrane antigen	14/14
CAM 5.2	12/14
34βE12	12/14
Cytokeratin 7	10/14
Cytokeratin 20	1/14
Carcinoembryonic antigen	4/14
Neuron specific enolase	10/14
Chromogranin	0/14
Synaptophysin	0/14
S-100 protein	6/14
Neurofilament protein	0/14
Glial fibrillary acidic protein	2/14
Muscle specific actin (HHF35)	7/14
Leu7 (CD57)	1/13
Vimentin	8/14
Ewing's marker (MIC-2)	7/14
Leukocyte common antigen	0/14
HMB-45	0/14
Desmin	0/13

disease includes other mucosal sites of the head and neck,[10] as well as in the gastrointestinal tract[4] and lower respiratory tract.[10] Metastases occur via lymphatics and blood vessels to lymph nodes and viscera, including the lungs, bone, skin, and brain.[1,5,6,10] Metastases include both basaloid and squamous cell components. BSCC require aggressive multimodality therapy, including radical surgical excision, neck dissection, radiotherapy, and often chemotherapy.[1,5,6,9] Although several studies have shown that stage for stage, the prognosis of BSCC is similar to that of conventional squamous cell carcinoma,[3,5] given the tendency for BSCC to present with advanced clinical stage disease, the prognosis associated with this tumor is poor. Of the 40 cases reported by Banks et al.[5] 31 (78%) were Stage III or IV tumors. Similarly, Ereño et al.[7] and Ferlito et al.[10] separately reported that 86% (6 of 7) and 80% (12 of 15) of their cases, respectively, presented with Stage III or IV tumors. The staging of tumors was made according to the guidelines established by the American Joint Committee on Cancer.[31] BSCC often is a rapidly fatal neoplasm with high mortality rates within the first year after diagnosis.[1,6,10] DNA ploidy studies of BSCC have not been predictive of the biologic potential of these tumors.[2,6]

The cell of origin for BSCC has been suggested to be a totipotential cell capable of divergent differentiation located in the basal zone of the surface epithelium or in the minor salivary glands of the submucosa.[1] The cell of origin most likely is from the surface epithelium given the occurrence of coexisting severe surface epithelial dysplasia or carcinoma in situ, as well as direct continuity of the invasive carcinoma to the overlying epithelium. The pathologic features of BSCC are dominated by the presence of a basaloid cell infiltrate with hyperchromatic nuclei and scanty cytoplasm. There is nuclear pleomorphism and increased mitotic activity, including atypical mitoses. Usually, the nuclei at the periphery of the neoplastic lobules are aligned in a linear orientation, so-called nuclear palisading. This feature may be limited in extent. In conjunction with the basaloid cell component, BSCC include foci of squamous differentiation. The squamous cell foci represent the minor cellular component and include keratinization, surface epithelial dysplasia, carcinoma in situ, or invasive squamous cell carcinoma. The squamous cell component always is present but varies in any given case from readily ap-

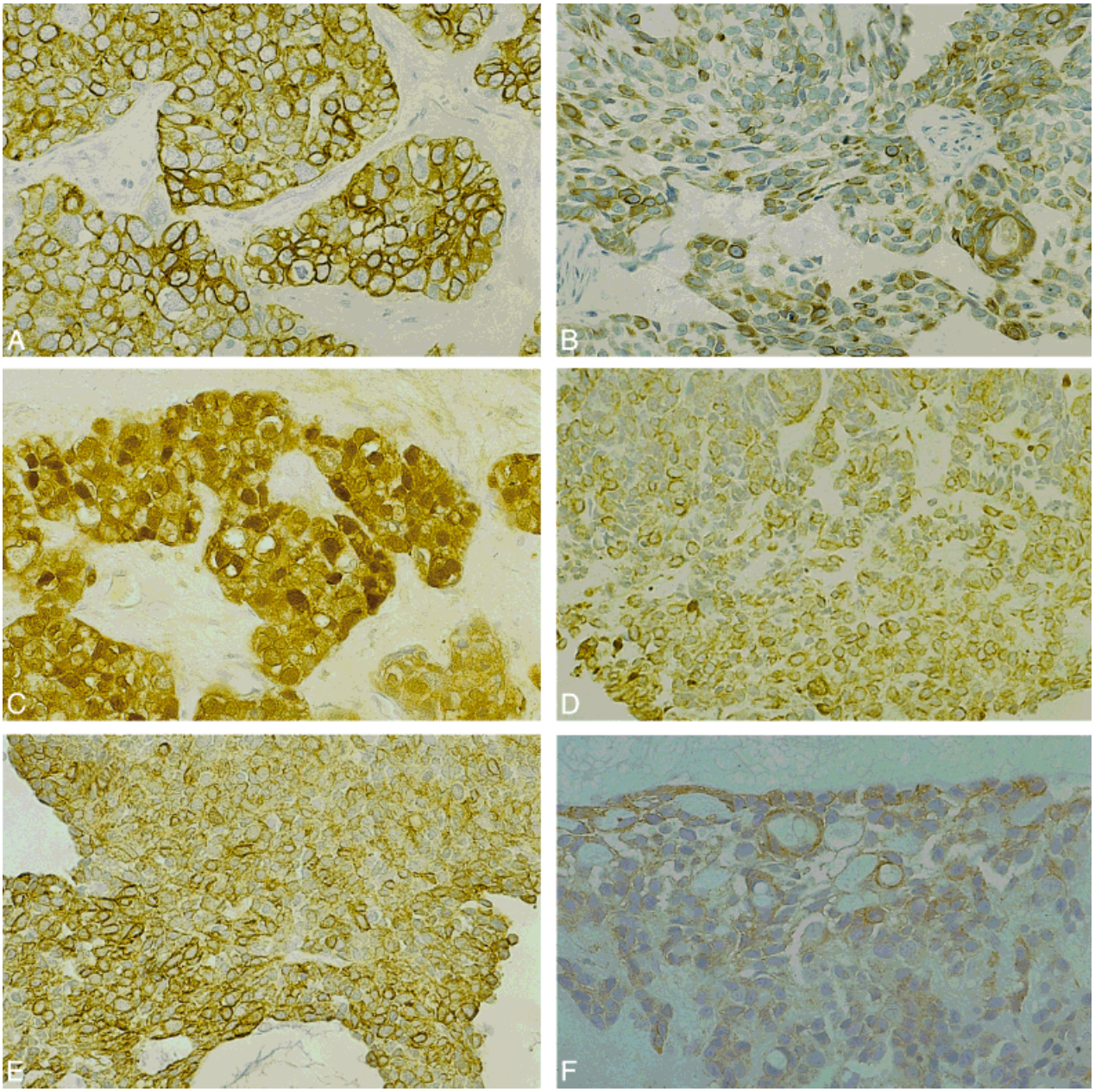

FIGURE 7. The immunohistochemical antigenic profile of sinonasal basaloid squamous cell carcinoma included: (A) keratin cocktail (Case 3), (B) 34βE12 (Case 1), (C) S-100 protein (Case 12), (D) vimentin with a perinuclear punctate pattern (Case 2), (E) smooth muscle actin (Case 12), and (F) Ewing's marker (Case 14).

parent to representing limited areas of the tumor. BSCC originate from the surface epithelium and are infiltrative tumors usually with a solid or lobular growth. Central or comedo-type necrosis is a common finding. Additional growth patterns include cribriform, cords, trabeculae, and gland-like or cystic. These growth patterns coupled with the basaloid cell infiltrate and the tendency to have associated intercellular deposition of eosinophilic hyalin or mucohyalin (basement membrane-like) material simulates the appearance of (minor) salivary gland tumors. Recently, Muller and Barnes[8] reported two cases of BSCC with an unusual spindle cell component. Two of our cases showed foci of fascicular growth with spindle-shaped cells. In addition, we found true neural type rosettes in two of our cases, one of which had associated foci of calcifications. To the best of our knowledge, neither neural-type rosettes or microcalcifications previously have been reported in BSCC of any site.

The immunohistochemical profile of the cases in

our series included consistently positive staining with one and usually multiple epithelial markers, including cytokeratin cocktail, CAM 5.2, 34βE12, EMA, or CK7. The distribution and intensity of the staining varied but was present in both the squamous and basaloid cell components. Tsang et al.[22] reported poor or absent cytokeratin reactivity in the basaloid component in their series of cases. We did not experience such an occurrence in our cases although in areas of any given tumor the basaloid cell components showed limited to absent cytokeratin reactivity. It is interesting to note that CK20 was absent in 13 of the 14 cases, suggesting that differential staining reactions between CK7 and CK20 may play a role in the diagnosis of BSCC. CEA was present in four cases and tended to localize to the squamous differentiated components. In none of the cases was there a dot-like pattern of cytokeratin staining that could be observed in neuroendocrine neoplasms. Furthermore, all our cases were negative with chromogranin and synaptophysin, and with NFP. NSE, S-100 protein, GFAP, and Leu7 variably were positive and tended to be focal and weakly reactive. However, in several cases there was diffuse and intense NSE and S-100 protein reactivity. In these cases, a variety of epithelial markers also were diffusely and intensely positive. In none of the cases was there a sustentacular cell-like distribution of the S-100 protein staining along the periphery of the neoplastic lobules. The variability of NSE and S-100 protein staining also was present in the cases reported by Banks et al.[5]

In eight of our cases there was vimentin reactivity. Barnes et al.[9] reported a peculiar pattern of vimentin staining with delicate perinuclear rimming, frequently with a small dot appearance. We were able to identify a similar pattern of vimentin staining in two of our cases, but in the other six cases the reactivity was distributed evenly in the cytoplasm with no specific staining pattern. Vimentin reactivity was limited to the basaloid cell component. Muscle specific actin and smooth muscle actin reactivity was present in seven and six cases, respectively. Actin reactivity is unusual for BSCC and Banks et al.[5] failed to identify actin (HHF35) staining in 35 cases. However, several other studies have reported actin reactivity in BSCC.[9,10,17,22,32] The actin reactivity predominantly was localized to the basaloid cell component. Unlike Tsang et al.[32] we did not find poor to absent cytokeratin expression in those cells showing actin staining. It is interesting to note that seven of our cases showed reactivity with Ewing's marker (CD99). This was an unexpected finding that we believe has no implication vis-a-vis categorization in the Ewing's sarcoma or primitive (peripheral) neuroendocrine tumor (ES/PNET) class of neoplasms. Ewing's marker is not restricted to ES/PNET but has been reported in a variety of other tumor types, including lymphoblastic lymphoma, other hematolymphoid malignancies, rhabdomyosarcoma, small cell osteosarcoma, mesothelioma, synovial sarcoma, leiomyosarcoma, desmoplastic small round cell tumor, Wilms' tumor, pancreatic endocrine tumors, and other neoplasms.[33,34]

To the best of our knowledge, we could only identify three previously reported cases of sinonasal tract BSCC.[5,18,19] Of these three sinonasal BSCC, two were included in larger series of BSCC with no detailed clinical or histopathologic descriptions provided.[5,18] The report by Wan et al.[19] provides a detailed clinical and pathologic description of the tumor. Their patient, a 67-year-old man, presented with epistaxis and was found to have a large fleshy tumor along the middle meatus of the left nasal cavity. Radiographic evaluation showed the tumor to be extensively invasive with extension into adjacent anatomic structures and osseous destruction.[19] Of the three previously reported cases of sinonasal BSCC, the gender was cited only in two of the cases, both occurring in males.[18,19] In the cases herein reported, there were an equal number of men and women with a median age of 66.5 years (range, 32–86 years). The most common clinical symptoms reported included nasal obstruction, a mass lesion, or bleeding. Banks et al.[5] implicate tobacco and alcohol consumption as risk factors in the development of BSCC. In six of our cases, there was a significant history of either tobacco or alcohol use. Prior radiation exposure also has been implicated in the possible development of these tumors.[19] Two of our cases (Cases 8 and 14) had a history of radiation exposure to the face or sinonasal region. In Case 14, the patient was treated with radiation to the face for childhood acne decades before the development of his intranasal BSCC. In Case 8, radiation was used for the treatment of a purported olfactory neuroblastoma 6 years prior to the development of her sinonasal BSCC. Unfortunately, material from her olfactory neuroblastoma was unavailable for histologic review. In this patient, the BSCC occurred in the ethmoid sinuses and involved the cribriform plate. The histology of the most recent tumor unequivocally was a BSCC (Fig. 3A). Furthermore, CD99 reactivity was present focally in this patient's BSCC, a finding not identified in association with olfactory neuroblastoma.[35] It is conceivable that this patient's original tumor also was a BSCC. Nevertheless, this history of radiation exposure matches the experience reported by Wan et al.[19] suggesting a possible etiologic role of radiation in the development of BSCC. In one of our cases (Case 11), the patient had chromate exposure and in another

case (Case 5) the patient had significant exposure to paint solvents but to our knowledge there is no known association between exposure to either chromates or paint solvents and the development of BSCC. Wan et al.[16] found EBV virus RNA by in situ hybridization in three cases of nasopharyngeal BSCC. However, these authors did not find evidence of EBV in 13 cases of BSCC in other sites of the upper aerodigestive tract. Similarly, Weiss et al.[18] found no evidence of EBV in five cases of BSCC in various upper aerodigestive mucosal sites. These findings suggest that EBV may play a role in the development of site specific nasopharyngeal BSCC but not for BSCC arising in other upper aerodigestive mucosal sites. To this end, we did not find EBV-LMP in any of our cases.

BSCC is an aggressive tumor, often with an advanced clinical stage disease at presentation, including extensive local invasion, multifocality, metastatic disease, and short survival periods. Such was the occurrence in the cases reported in the current study. Seven of the 14 patients (Cases 1, 3–6, 10, and 13) were dead of disease at last follow-up, over periods ranging from 6 months to 8 years. Of the remaining patients who were alive at last follow-up, four had recurrent/persistent disease or metastatic disease (Cases 7, 8, 11, and 12), one was lost to follow-up (Case 2), and in one patient the tumor was diagnosed with only 1 month follow-up (Case 14). In total, five patients had metastatic disease (Cases 4, 6, 7, 10, and 11) to regional lymph nodes, lung, bone, and/or the brain. In two patients there was direct extension to the dura (Case 8) or direct invasion of the brain (Case 5). Given the tendency for local invasion or regional metastases, we considered the possibility of direct extension or metastasis of BSCC to the sinonasal tract from a more common primary tumor site in the head and neck. In none of our cases was there prior, concurrent, or subsequent evidence of primary BSCC developing in any other location. In none of our cases was there multifocal disease prior to, concurrent with, or after the diagnosis of sinonasal BSCC.

In general, the differential diagnosis of BSCC includes adenoid cystic carcinoma and small cell undifferentiated neuroendocrine carcinoma. In the sinonasal region, the differential diagnosis is expanded to include olfactory neuroblastoma and sinonasal undifferentiated carcinoma. Table 3 delineates the diagnostic features that assist in differentiating BSCC from these and other tumors.

Adenoid cystic carcinoma (ACC) is a malignant tumor of the salivary glands. Most often the major salivary glands are affected but ACC in minor salivary glands can occur, including in the sinonasal tract. The short term biologic behavior of ACC is much less aggressive than that of BSCC, with 5-year survival rates of 75%.[36] Regional lymph node metastases are infrequent at presentation and distant metastases occur late in the disease process. Immunohistochemical stains would not appear to assist in differentiating ACC from BSCC because both are reactive with a variety of markers, including cytokeratin, vimentin, S-100 protein, NSE, desmin, and smooth muscle actin.[36] Our findings, as well as those of other authors[5,6,9,10] would be in contrast to those of Klijanienko et al.[37] who found that vimentin and S-100 protein consistently were negative in BSCC and reactive in ACC. Along these lines, Morice and Ferreiro[38] found smooth muscle actin in 73% of ACC whereas all their cases of BSCC were negative for smooth muscle actin. This absence of smooth muscle actin also was reported by Banks et al.[5] but is not our experience nor that of other authors.[9,10,17,22,32] There are some studies suggesting that proliferative markers such as Ki-67 and MIB-1 may assist in separating BSCC from ACC with BSCC showing high Ki-67 (MIB-1) reactivity and ACC showing low Ki-67 (MIB-1) reactivity.[9,10] However, Vargas et al.[39] found relatively high Ki-67 (MIB-1) reactivity in ACC. In our experience, we do not find the immunohistochemical reactive patterns of BSCC and ACC significantly different as to allow distinction between these two tumors. Hewan-Lowe and Dardick[40] identified ultrastructural features that assist in differentiating BSCC from ACC. These authors compared the ultrastructural features of three BSCC and three ACCs and found that the BSCC had features of squamous cell carcinoma, including cell groups with numerous and prominent tonofilament bundles, increased desmosomes, and epithelial pearls. These features were not present in the adenoid cystic carcinomas.[40] Features of glandular differentiation were exclusively identified in the ACCs but not in the BSCC, including oligocilia and lumina (large lumina and smaller compressing ones). Of note, Hewan-Lowe and Dardick[40] reported that the ultrastructural features of the reduplicated basement membrane material in both BSCC and ACC were the same.

The polymorphous growth of BSCC, presence of basement membrane-like material, and immunohistochemical profile of BSCC may suggest a diagnosis of other salivary gland tumors such as polymorphous low grade adenocarcinoma (PLGA). However, the pleomorphic cells of BSCC contrast sharply with the bland isomorphic cell population that typifies PLGA. It should be noted that Lloreta et al.[41] reported a case of PLGA of the sinonasal tract. In our opinion, the description and illustrations of that tumor are more suggestive of BSCC than PLGA.

Small cell undifferentiated neuroendocrine carci-

TABLE 3
BSCC Differential Diagnosis—Contrasting Features

Tumor type	Light microscopy	Immunohistochemistry	Electron microscopy
ACC	• Mucoserous gland origin; no surface connection • Nuclei: small, uniform, hyperchromatic, angulated, scant cytoplasm • Minimal mitotic activity, minimal pleomorphism • No squamous differentiation, ductal type foci are present • No squamous differentiation, ductal type foci are present	• Not helpful; ACC shares similar immunoreactivity with BSCC	• Lack features of squamous differentiation (tonofilaments, desmosomes, intercellular bridges) or glandular differentiation (oligocilia, lumina)
SCUNC	• Growth in solid nests or sheets • Nuclei: hyperchromatic, pleomorphic with stippled/granular chromatin • Scant cytoplasm, necrosis, increased mitotic activity • No surface epithelial dysplasia, CIS, or invasive carcinoma • No peripheral palisading • Absence of reduplicated basement membrane material	• Perinuclear dot-like cytokeratin reactivity, neuroendocrine markers positive, absence of reactivity with 34βE12	• Neurosecretory granules
ONB: Grades 3, 4	• True-neural rosettes (Flexner-Wintersteiner) may be present • Carcinomatous components (adeno- or squamous) occur only rarely • No surface epithelial changes or peripheral palisading • Absence of reduplicated basement membrane material	• Consistent NSE reactivity; S-100 protein reactivity usually at periphery of neoplastic lobules; little to absent cytokeratin reactivity variable reactivity with chromogranin and synaptophysin; CD99 negative	• Neuronal processes and dense core granules
SNUC	• Anaplastic tumor without histologic differentiation (squamous, glandular, other) • Growth: lobular, trabecular, cords, solid to sheet-like (no cribriform or tubular patterns) • Pleomorphic, enlarged hyperchromatic nuclei, prominent nucleoli • Scant cytoplasm, increased mitotic activity with atypical forms, necrosis • Absence of reduplicated basement membrane material	• Consistent reactivity with epithelial markers usually negative for neuroendocrine markers, NSE, S-100 protein	• Neurosecretory granules may be present
ASC	• Mixture of squamous cell carcinoma and adenocarcinoma (gland formation and/or mucocytes) • Arises from surface epithelium with surface dysplasia and/or CIS giving rise to invasive carcinoma • Absence of basaloid component with peripheral palisading or comedo-type necrosis • Absence of reduplicated basement membrane material • Presence of glandular differentiation with intracellular and intraluminal mucin (mucicarmine and PAS positive, diastase resistant)	• No specific differentiating features	• No specific differentiating features

BSCC: basaloid squamous cell carcinoma; ACC: adenoid cystic carcinoma; SCUNC: small cell undifferentiated neuroendocrine carcinoma; ONB: olfactory neuroblastoma; SNUC: sinonasal undifferentiated carcinoma ASC: adenosquamous carcinoma; SMA: smooth muscle actin; CIS: carcinoma in situ; NSE: neuron specific enolase; PAS: periodic acid–Schiff stain.

nomas (SCUNC) are uncommon sinonasal tract tumors. SCUNC can be confused with BSCC especially in limited biopsy sampling. The distinction between these tumors is important due to differences in therapeutic options between SCUNC and BSCC. The treatment of choice in SCUNC is systemic chemotherapy whereas in BSCC surgical resection remains the standard of care. Both BSCC and SCUNC show immunoreactivity with cytokeratin but the reactive pattern in SCUNC is often dot-like, a finding that is not present in BSCC. Neuroendocrine markers, including chromogranin and synaptophysin, are positive in SCUNC and negative in BSCC. Morice and Ferreira[38] reported that 34βE12 plays a role in distinguishing BSCC from SCUNC. They reported that 34βE12 was present in 22 of 23 BSCC but was absent in all 10 cases of SCUNC. Ultrastructurally, neurosecretory granules are characteristic of SCUNC whereas they are absent in BSCC.[1,40]

Olfactory neuroblastomas (ONB) are malignant neoplasms believed to arise from the olfactory mem-

brane of the sinonasal tract in the superior aspect of the nasal cavity. ONB can be classified into four histologic grades based on their degree of differentiation.[42] It is the higher histologic grade ONB that could present diagnostic difficulties with BSCC. Sinonasal BSCC share histologic features similar to high grade ONB, including the presence of true neural-type rosettes as observed in two of our cases. In contrast to ONB, the presence of surface epithelial changes (dysplasia or carcinoma in situ), direct continuity between the surface epithelium and invasive tumor, and peripheral palisading as observed in BSCC are not found in ONB (of any histologic grade). Gaudin and Rosai[43] reported that a prominent vascular proliferation in the form of glomeruloid vascular spaces may accompany different types of neuroendocrine tumors, including ONB. This feature was not found in our cases of BSCC nor to our knowledge has it been previously reported in BSCC.

Sinonasal undifferentiated carcinoma (SNUC) is a highly aggressive malignant neoplasm of the nasal cavity and the paranasal sinuses. The cell of origin has not been identified definitively and the likelihood is that this tumor originates from the schneiderian epithelium. SNUC is an anaplastic neoplasm with the absence of any histologic differentiating features (e.g., squamous, glandular, other). The presence of squamous foci in BSCC would exclude a diagnosis of SNUC. Further, the cribriform and tubular growth patterns and the presence of reduplicated basement membrane-like material observed in BSCC are not features that are observed in SNUC.

Adenosquamous carcinoma (ASC) is an underreported high grade variant of squamous cell carcinoma comprised of an admixture of squamous cell carcinoma and adenocarcinoma. ASC occurs throughout the upper aerodigestive tract, including the larynx, hypopharynx, oral cavity, and sinonasal cavity. Like BSCC, ASC arises from surface epithelium with evidence of surface dysplasia and/or carcinoma in situ directly giving rise to invasive carcinoma. The squamous component prominently is observed and varies from well to poorly differentiated carcinoma with keratinization (individual cell, keratin pearl formation, or dyskeratosis) and intercellular bridges. The adenocarcinoma component includes gland formation and/or mucocytes. The neoplastic infiltrate in ASC is pleomorphic with increased mitotic activity, associated necrosis, and widespread invasion. In contrast to BSCC, ASC has a prominent squamous cell component, an absence of basaloid cells with peripheral nuclear palisading, and the presence of glandular differentiation, including intracellular and intraluminal epithelial mucin (mucicarmine and diastase-resistant, PAS positive material).

Cutaneous basal cell carcinoma (BCC) shares some histologic features with mucosal BSCC. Cutaneous BCCs originating from the nasal vestibule or directly invading from the skin of the nose or nasolabial area may present some diagnostic difficulties with sinonasal BSCC. The histologic features of BSCC, including the associated epithelial dysplasia, squamous differentiation, marked nuclear pleomorphism, high mitotic rate with atypical mitoses, and comedonecrosis, should allow for distinguishing these neoplasms. It is important for clinicians and pathologists to be aware that mucosal BSCC is distinct from cutaneous BCC with vastly different histogenesis and, more important, completely different treatment protocols and biologic behavior. Ameloblastomas may originate from within the sinonasal tract without connection to gnathic bones.[44] Ameloblastomas are comprised of basaloid-appearing cells with peripheral nuclear palisading. However, in contrast to BSCC, ameloblastomas include the presence of a stellate reticulum and although there is nuclear palisading of the peripheral cells, there nuclei orient away from the basement membrane, so-called reverse polarity.

BSCC of the sinonasal tract is an uncommon but distinct malignant tumor that shares light microscopic and immunohistochemical features, as well as biologic behavior, with BSCC of more common mucosal sites of the upper aerodigestive tract. Given the presence of surface epithelial dysplastic alterations with direct continuity between the surface epithelium and invasive tumor, it is reasonable to consider BSCC to be a surface epithelial-derived neoplasm rather than originating from minor salivary glands. Previous radiation exposure may represent a risk factor for the development of sinonasal BSCC. Based on our findings, alcohol and tobacco use or viral induction do not appear to represent etiologic agents in the development of BSCC confined to the sinonasal tract. Sinonasal BSCC is an aggressive tumor requiring equally aggressive therapeutic intervention. The treatment of choice is complete surgical excision supplemented with radiotherapy and, in patients with metastatic disease, chemotherapy. Despite all attempts to control disease, sinonasal BSCC have increased morbidity and mortality and frequently are fatal within 12 months from the time of diagnosis. Histologic differentiation from other sinonasal tract tumors with overlapping histologic and immunohistochemical characteristics may have clinical and therapeutic significance.

REFERENCES

1. Wain SL, Kier R, Vollmer RT, Bossen EH. Basaloid squamous cell carcinoma of the tongue, hypopharynx and larynx. Report of 10 cases. *Hum Pathol* 1986;17:1158–66.
2. McKay MJ, Bilous AM. Basaloid squamous carcinoma of the hypopharynx. *Cancer* 1989;63:2528–31.
3. Luna MA, El Naggar A, Parichatikanond P, Weber RS, Batsakis JG. Basaloid squamous carcinoma of the upper aerodigestive tract. Clinicopathologic and DNA flow cytometric analysis. *Cancer* 1990;66:537–42.
4. Seidman JD, Berman JJ, Yost BA, Iseri OA. Basaloid squamous cell carcinoma of the hyopopharynx and larynx associated with second primary tumors. *Cancer* 1991;68:1545–9.
5. Banks ER, Frierson HF Jr., Mills SE, George E, Zarbo RJ, Swanson PE. Basaloid squamous cell carcinoma of the head and neck. A clinicopathologic and immunohistochemical study of 40 cases. *Am J Surg Pathol* 1992;16:939–46.
6. Raslan WF, Barnes L, Kraus JR, Contis L, Killeen R, Kapadia SB. Basaloid squamous cell carcinoma of the head and neck: a clinicopathologic and flow cytometric study of 10 new cases with review of the English literature. *Am J Otolaryngol* 1994;15:204–11.
7. Ereño C, Lopez JI, Sanchez JM, Toledo JD. Basaloid-squamous cell carcinoma of the larynx and hyopoharynx. A clinicopathologic study of 7 cases. *Pathol Res Pract* 1994;190:186–93.
8. Muller S, Barnes L. Basaloid squamous cell carcinoma of the head and neck with a spindle cell component. An unusual histologic variant. *Arch Pathol Lab Med* 1995;119:181–2.
9. Barnes L, MacMillan C, Ferlito A, Rinaldo A, Altavilla G, Doglioni C. Basaloid squamous cell carcinoma of the head and neck: clinicopathologic features and differential diagnosis. *Ann Otol Rhinol Laryngol* 1996;105:75–82.
10. Ferlito A, Altvilla G, Rianldo A, Doglioni C. Basaloid squamous cell carcinoma of the larynx and hypopharynx. *Ann Otol Rhinol Laryyngol* 1997;106:1024–35.
11. Lovejoy HM, Mathews BL. Basaloid squamous cell carcinoma of the palate. *Otolaryngol Head Neck Surg* 1992;106:159–62.
12. Cadier MA, Kelly SA, Parkhouse N, Brough MD. Basaloid squamous cell carcinoma of the buccal cavity. *Head Neck* 1992;14:387–91.
13. Coppola D, Catalano E, Tang C-K, Elfenbein IB, Harwick R, Mohr R. Basaloid squamous cell carcinoma of floor of mouth. *Cancer* 1993;72:2299–305.
14. Campman SC, Gandour-Edwards RF, Sykes JM. Basaloid squamous cell carcinoma of the head and neck. Report of a case occurring in the anterior floor of the mouth. *Arch Pathol Lab Med* 1994;118:1229–32.
15. Hellquist HB, Dahl F, Karlsson MG, Nilsson C. Basaloid squamous cell carcinoma of the palate. *Histopathology* 1994;25:178–80.
16. Wan SK, Chan JKC, Lau WH, Yip TTC. Basaloid squamous carcinoma of the nasopharynx. *Cancer* 1995;76:1689–93.
17. Saltarelli MG, Fleming MV, Wenig BM, Gal AA, Mansour KA, Travis WD. Primary basaloid squamous cell carcinoma of the trachea. *Am J Clin Pathol* 1995;104:594–8.
18. Weiss LM, Movahed LA, Butler AE, Swanson SA, Frierson HF, Cooper PH, et al. Analysis of lymphoepithelioma and lymphoepithelioma-like carcinomas for Epstein-Barr viral genomes by in-situ hybridization. *Am J Surg Pathol* 1989;13(8):625–31.
19. Wan SK, Chan JKC, Tse KC. Basaloid squamous cell carcinoma of the nasal cavity. *J Laryngol Otol* 1992;106:370–1.
20. Hsu SM, Raine L, Fanger H. Use of avidin-biotin-peroxidase complex (ABC) in immunoperoxidase techniques: comparison between ABC and unlabeled antibody (PAP) procedures. *J Histochem Cytochem* 1981;29:577–80.
21. Tauchi K, Kakudo K, Machimura T, Makuuchi H. Superficial esophageal carcinoma with special reference to basaloid features. *Pathol Res Pract* 1990;186:450–4.
22. Tsang WYW, Chan JKC, Lee KC, Leung AKF, Fu YT. Basaloid squamous carcinoma of the upper aerodigestive tract and so-called adenoid cystic carcinoma of the oesophagus: the same tumour type? *Histopathology* 1991;19:35–46.
23. Abe K, Sasano H, Itakura Y, Nishihira T, Mori S, Nagura H. Basaloid-squamous carcinoma of the esophagus. A clinicopathologic, DNA ploidy, and immunohistochemical study of seven cases. *Am J Surg Pathol* 1996;20:453–61.
24. Brambilla E, Moro D, Veale D, Brichon PY, Stoebrer P, Paramelle B, et al. Basal cell (basaloid) carcinoma of the lung: a new morphologic and phenotypic entity with separate prognostic significance. *Hum Pathol* 1992;23:993–1003.
25. Moro D, Brichon P-Y, Brambilla E, Veale D, Labat F, Brambilla C. Basaloid bronchial carcinoma. A histologic group with a poor prognosis. *Cancer* 1994;73:2734–9.
26. Lin O, Harkin TJ, Jagirdar J. Basaloid squamous cell carcinoma of the bronchus. Report of a case with review of the literature. *Arch Pathol Lab Med* 1995;119:1167–70.
27. Suster S, Rosai J. Thymic carcinoma: a clinicopathologic study of 60 cases. *Cancer* 1991;67:1025–32.
28. Dougherty BG, Evans HL. Carcinoma of the anal canal: a study of 79 cases. *Am J Clin Pathol* 1985;83:159–64.
29. Ferry JA, Scully RE. "Adenoid cystic" carcinoma and adenoid basal carcinoma of the uterine cervix. A study of 28 cases. *Am J Surg Pathol* 1988;12:134–44.
30. Norris HJ, McCauley KM. Adenoid basal cell carcinoma. Unusual forms of adenocarcinoma of the cervix: and update. In: Rosen PP, Fechner RE, editors. Pathology annual. Part I. Norwalk: Appleton & Lange, 1993:88–9.
31. Head and neck. In: Beahrs OH, Henson DE, Hutter RVP, Kennedy BJ, editors. American Joint Committee on Cancer manual for staging of cancer. Fourth edition. Philadelphia: J.B. Lippincott Co., 1992:33–44.
32. Tsang WYW, Chan JKC. Basaloid squamous cell carcinoma of the upper aerodigestive tract [letter]. *Histopathology* 1992;20:462.
33. Stevenson AJ, Chatten J, Bertoni F, Miettinen M. CD99 (p30/32^{mic2}) neuroectodermal/Ewing's sarcoma antigen as an immunohistochemical marker. Review of more than 600 tumors and the literature experience. *Appl Immunohistochem* 1994;2:231–40.
34. Weidner N, Tjoe J. Immunohistochemical profile of monoclonal antibody O13: antibody that recognizes glycoprotein p30/32^{mic2} and is useful in diagnosing Ewing's sarcoma and peripheral neuroepithelioma. *Am J Surg Pathol* 1994;18:486–94.
35. Argani P, Perez-Ordoñez B, Xiao H, Caruana SM, Huvos AG, Ladanyi M. Olfactory neuroblastoma is not related to the Ewing family of tumors. Absence of EWS/FLI1 gene fusion and MIC2 expression. *Am J Surg Pathol* 1998;22:391–8.
36. Ellis GL, Auclair PL. Adenoid cystic carcinoma. In: Rosai J, Sobin LH, editors. Atlas of tumor pathology. Tumors of the salivary gland. Third series. Fascicle 17. Washington, DC: Armed Forces Institute of Pathology, 1996:203–28.

37. Klijanienko J, el-Naggar A, Ponzio-Prion A, Marandas P, Micheau C, Caillaud JM. Basaloid squamous cell carcinoma of the head and neck. Immunohistochemical comparison with adenoid cystic carcinoma and squamous cell carcinoma. *Otolaryngol Head Neck Surg* 1993;119:887–90.
38. Morice WG, Ferreiro JA. Distinction of basaloid squamous cell carcinoma from adenoid cystic and small cell undifferentiated carcinoma by immunohistochemistry. *Hum Pathol* 1998;29:609–12.
39. Vargas H, Sudlivosky D, Kaplan MJ, Regezi JA, Weidner N. Mixed tumor, polymorphous low-grade adenocarcinoma and adenoid cystic carcinoma of the salivary glands. Pathogenic implications and differential diagnosis by Ki67 (MIB1), BCL2, and S-100 immunohistochemistry. *Appl Immunhistochem* 1997;5:8–16.
40. Hewan-Lowe K, Dardick I. Ultrastructural distinction of basaloid-squamous carcinoma and adenoid cystic carcinoma. *Ultrastruct Pathol* 1995;19:371–81.
41. Lloreta J, Serrano S, Corominas JM, Ferrés-Padró E, Dardick I. Polymorphous low-grade adenocarcinoma arising in the nasal cavities with an associated undifferentiated carcinoma. *Ultrastruct Pathol* 1995;19:365–70.
42. Hyams VJ. Olfactory neuroblastoma (case 6). In: Batsakis JG, Hyams VJ, Morales AR, editors. Special tumors of the head and neck. Chicago: ASCP Press, 1982:24–9.
43. Gaudin PB, Rosai J. Florid vascular proliferation associated with neural and neuroendocrine neoplasms. A diagnostic clue and potential pitfall. *Am J Surg Pathol* 1995;19:642–52.
44. Shafer D, Thompson LCDR, Smith BC, Wenig BM. Ameloblastoma of the sinonasal tract. *Cancer* 1998;82:667–74.